

# Infection after fracture osteosynthesis – Part II: Treatment

*Journal of Orthopaedic Surgery*

25(1) 1–11

© Journal of Orthopaedic Surgery 2017

Reprints and permissions:

sagepub.co.uk/journalsPermissions.nav

DOI: 10.1177/2309499017692714

journals.sagepub.com/home/osj



Christian Fang<sup>1</sup>, Tak-Man Wong<sup>1,3</sup>, Kelvin KW To<sup>2</sup>,  
Samson SY Wong<sup>2</sup>, Tak-Wing Lau<sup>1</sup>, and Frankie Leung<sup>1,3</sup>

## Abstract

In the first part of this article, we have discussed the pathogenesis, clinical presentation, diagnosis and classification of infection after fracture osteosynthesis with implants, termed here as osteosynthesis-associated infection (OAI). Prolonged antibiotic treatment is usually necessary. Implant retention and maintenance of fracture stability to allow for fracture healing in spite of infection are allowed for OAI. Depending on the severity of infection, status of fracture healing and host status, the treatment follows five common pathways. These are non-operative treatment, debridement with implant retention, conversion of fixation, implant removal and suppression therapy. The decision-making process leading to each treatment pathway and challenging scenarios is discussed in detail.

## Keywords

biofilms, fracture fixation, prosthesis-related infections, surgical wound infection

## Introduction

The term osteosynthesis-associated infection (OAI) is defined as infection occurring after surgical fixation of fractures with internally placed implants. The goal of treatment is to eradicate infection, allow fracture healing, preserve body function and prevent its recurrence.<sup>1</sup> Presentation is heterogeneous and treatment is highly individualized. Because of a lack of properly conducted comparative studies, the current discussion is at best based on larger series by Torbert et al.,<sup>2</sup> Berkes et al.<sup>3</sup> and Rightmire et al.,<sup>4</sup> a number of smaller case series and heterogeneous studies.

The three most important factors in devising a treatment strategy for OAI are mechanical stability, time interval between fixation and infection and the presence of union. The other guiding factors are implant type, presence of collections, non-viable bone, graft or substitute, soft tissue and bone defect, joint involvement, host status and response to treatment. Patients requiring surgical treatment are best referred to subspecialized centres that are better equipped.<sup>5</sup> Patients should expect prolonged hospital stay, multiple surgeries and prolonged use of intravenous antibiotics. Optimization of the general nutritional status and co-morbid factors including smoking cessation is an important part of general management.<sup>6</sup>

## Fracture stability and implant retention

Although commonly considered as orthopaedic implant infection, OAI is fundamentally different from prosthetic joint infection (PJI). In PJI, permanent eradication is necessary but difficult because of a large potential joint space and sizable implants. Late haematogenous infection long after surgery is common in PJI while early infection is more common in OAI.

In OAI, implants can be definitively removed after fracture union. The potential dead space is smaller. Involved joints in OAI are lined by vulnerable living cartilage while cartilage preservation is irrelevant for PJI. For late PJI, the success rate of implant retention is as low as 15–54%,<sup>7</sup>

<sup>1</sup> Department of Orthopaedics and Traumatology, Queen Mary Hospital, University of Hong Kong, Pokfulam, Hong Kong

<sup>2</sup> Department of Microbiology, Queen Mary Hospital, University of Hong Kong, Pokfulam, Hong Kong

<sup>3</sup> Shenzhen Key Laboratory for Innovative Technology in Orthopaedic Trauma, University of Hong Kong-Shenzhen Hospital, Shenzhen, China

## Corresponding author:

Christian Fang, Department of Orthopaedics and Traumatology, Queen Mary Hospital, University of Hong Kong, Pokfulam, Hong Kong.  
Email: fangcx@gmail.com

while for OAI, when fracture stability is maintained, the rate of successful hardware retention is 56–86%.<sup>3,4</sup>

The majority of OAI occurs within 10 weeks from surgery.<sup>2</sup> Even in the presence of infection, fractures can still heal provided that it is vascular and stable.<sup>8</sup> The ability to heal is poor if there is sequestrum, bone defect and implant loosening. Stability is important as movement across the fracture causes soft tissue irritation, damage to revascularization, haematoma and dead space formation. These factors are detrimental to both fracture healing and control of infection.<sup>9</sup>

An infected and united fracture is easier managed than an infected and non-united fracture.<sup>10</sup> Even though the eradication of biofilm organisms maybe difficult with the presence of implants, suppression of infection is possible as long as collections, tissue necrosis and dead spaces are minimal. If the hardware can provide much stability to the fracture, it is preferentially retained until fracture union.

## Treatment strategy

### *Acute infection 2 weeks after surgery*

*Around one-quarter of all OAIs presents within 2 weeks.* They are sometimes regarded as ‘superficial infections’ when there is only mild wound edge erythema, superficial discharge and breakdown. Ultrasonography or computed tomography (CT) scans are helpful in detecting deep-seated collections which are often not confirmable clinically. Any deep-seated collections should be drained and sent for microbiological tests. If it is certain that the infection is recent and superficial, empirical intravenous antibiotics for 2 weeks without surgical debridement may suffice. In situations with large deep-seated collections, persistent discharge or breakdown of wound edges, a formal debridement with implant retention is indicated. Pre-emptive drainage of wound haematomas that are doubtful of being infected is indicated, especially in high-risk regions like the tibia.

### *Delayed infection before expected fracture union*

In delayed OAI occurring from 3 to 10 weeks after osteosynthesis, fracture healing is often incomplete. Biofilm formation and osteomyelitis are moderate. The surgical strategy is similar to the debridement, antibiotics and implant retention protocol in PJI.<sup>11</sup> Routine removal of implants is best avoided as this may result in gross instability and worsening of infection. Smoking, diabetes, medical comorbidities, pseudomonas infection and open fractures are risk factors for failed implant retention. External fixation with implant removal is necessary when the duration of infection is prolonged or when implants are loose.<sup>4</sup>

From the two larger retrospective series by Berkes et al.<sup>3</sup> and Rightmire et al.,<sup>4</sup> the expected rate of successful hardware retention with debridement and systemic antibiotics is

68–71%. Despite fracture healing being usually successful, around 50% of implants would require eventual removal for unresolved infections. OAIs with intramedullary (IM) nails are thought to be associated with delayed diagnosis and are more difficult to access surgically. Despite this, Chen et al.<sup>12</sup> reported high rates of successful retention of IM nailing in patients with OAI after femur fractures. On the other hand, patients who underwent removal and external fixation experienced a higher incidence of non-union and other complications.

### *Late infection with non-union*

When infection presents at more than 10 weeks after osteosynthesis, it is nearly always well established and deep seated. These are often regarded as infected non-unions. Delayed diagnosis, implant loosening, tissue necrosis, mature biofilm and sequestrum formation are usual. External bracing alone is unstable and non-surgical treatment is likely to fail. Loose implants are no longer functional and therefore must be removed or revised. The sequestrum should be excised. Infection must be controlled before reconstruction of bone defects. There is a low threshold for conversion to external fixation.<sup>12,13</sup> In situations where this is not possible, revision of the internal fixation with stable bridging implants is indicated. In a systematic review of 34 case series, a fracture union rate of 66–100%<sup>14</sup> is generally achievable by single- or two-stage surgery. However, up to 60% of patients may have persistence of infection after fracture union.

Indolent infections must be suspected for all aseptic non-unions, delayed unions and implant loosening. Specimen should be routinely sent for microbiology and histological examination. Around 20% of these cultures specimen may return as ‘surprise’ positives. Still, the chance of successful union is 80% when these situations are adequately managed with antibiotics.<sup>15</sup>

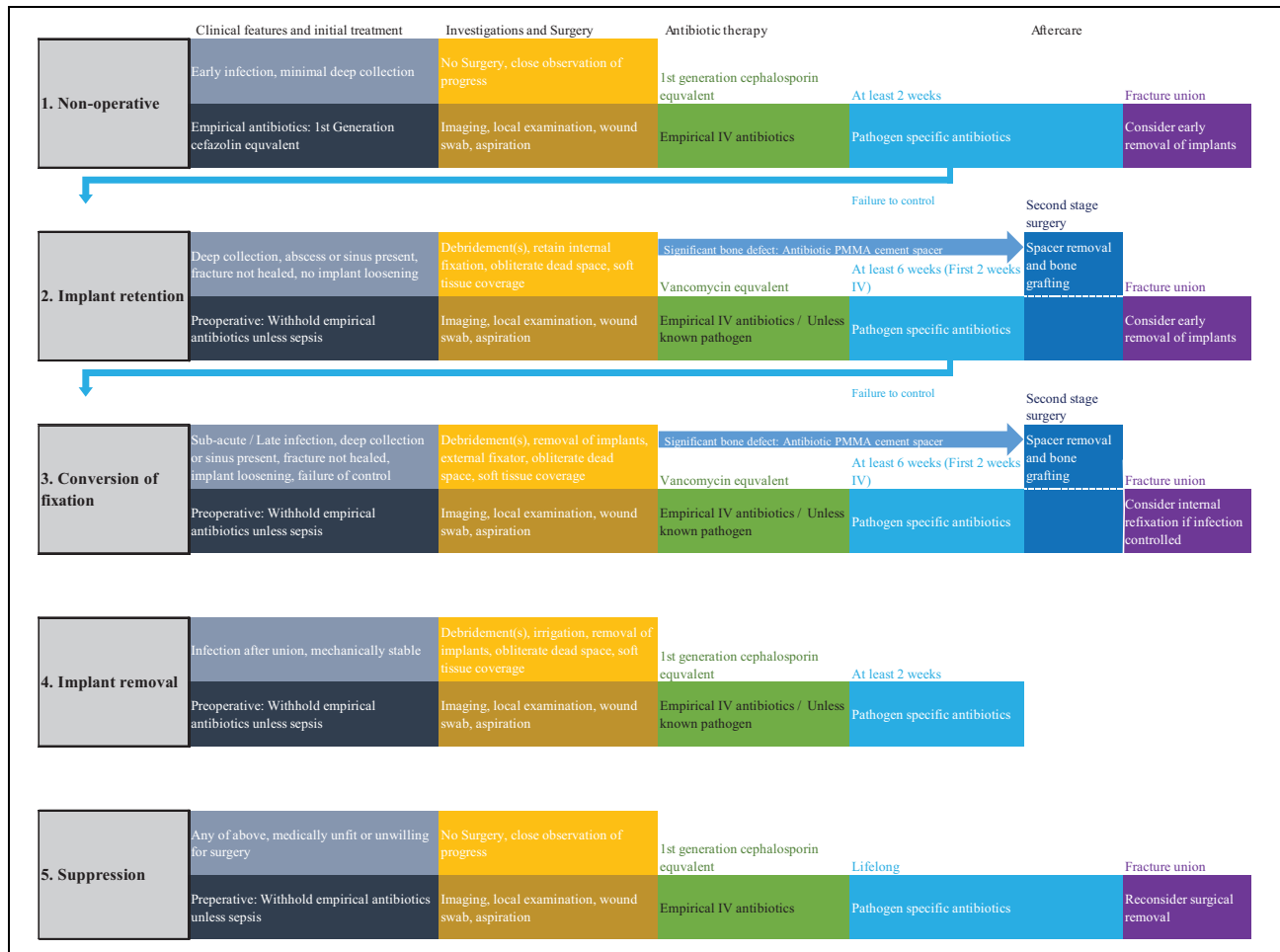### *Infection after fracture union*

Management of infection after fracture union is usually straightforward by debridement and implant removal. In patients with previous OAI, implants should be pre-emptively removed because infections are likely to recur from biofilms.<sup>3,16</sup> CT scans are useful in clarifying the status of union when radiographs are doubtful. Patients associated with osteomyelitis, septic arthritis or soft tissue defects are managed accordingly following standard principles (Figure 1).

## General surgical considerations

### *Surgical debridement*

Debridement of necrotic soft tissue, debris, pus and haematoma should proceed aggressively, while skin at the wound margins is sparingly removed. The implant and fracture are



**Figure 1.** Outline of five different treatment pathways for OAI in different clinical situations. The management pathway should be stepped up upon failure of control from (1) non-operative treatment to (2) implant retention and lastly to (3) conversion of fixation. (4) Implant removal is performed after fracture union and (5) suppression therapy is recommended for poor surgical candidates. OAI: osteosynthesis-associated infection.

assessed for stability. Exchange of implants reduces the biofilm burden and allows for access to locations covered by the plate. Devitalized bone should be removed in severe and persistent infections even when structurally relevant. Wound lavage is performed using a large amount of normal saline. The use of antiseptics and high-flow pulsatile systems<sup>17</sup> is weakly supported by evidence but often performed. Sizable bone voids can be filled with antibiotic-impregnated spacers, and soft tissue defects are controlled by meticulous closure, vacuum assistance or flaps. Primary wound closure is preferred especially when there is exposed bone.

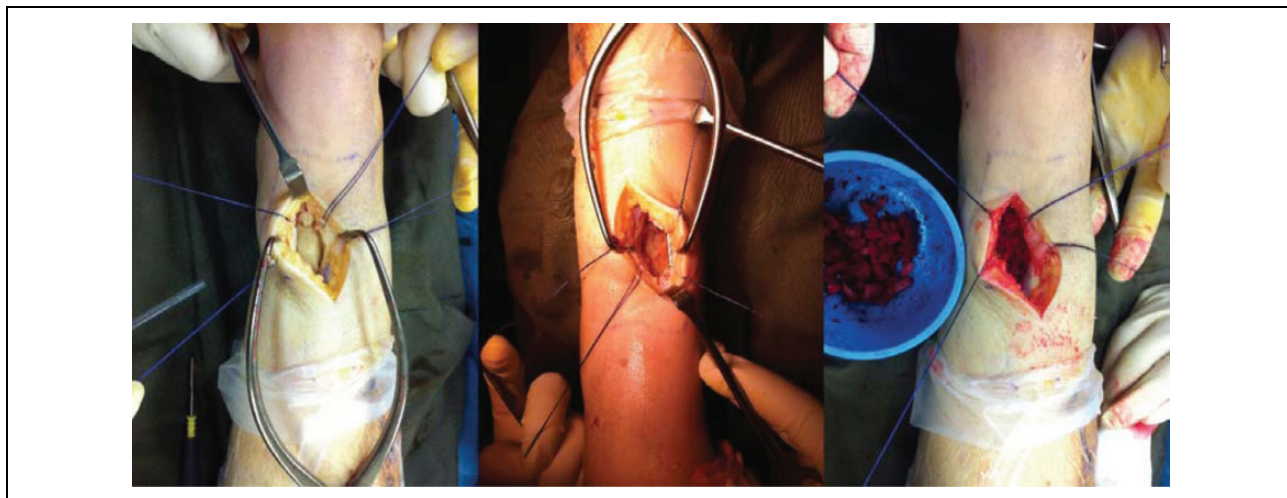
A majority of patients will require more than two or three debridements.<sup>4,16</sup> A second look debridement should be routinely planned and explained to patients before performing the first. When there is doubtful tissue viability and extensive tissue necrosis, re-exploration and debridement should be performed every 2–3 days until a grossly non-infected base with healthy bleeding bone and soft tissue is obtained.

### Use of external fixators

Complete implant removal and conversion to external fixator is indicated when there is failure of control after repeated debridement or when there are multiple adverse local and systemic factors.<sup>12</sup> Illizarov-type ring external fixators provide better fixation in cancellous bone. They are particularly useful in the periarticular region where preservation of joint motion is a concern. The success rate of ring external fixation is high.<sup>18–20</sup> The main drawbacks include bulkiness, patient discomfort and very high rate of pin tract infections. In patients with low systemic risks and favourable soft tissue, conversion back to internal fixation can be considered after the infection is controlled.<sup>21</sup>

### Local antimicrobial therapy

Local antibiotic therapy is not strongly evidence-based but commonly practiced.<sup>22</sup> Knowledge is borrowed from PJI where local antibiotic concentrations are increased with



**Figure 2.** The PMMA-induced spacer technique at the bone grafting stage in a patient with distal tibia bone defect. After control of the infection, the fibrous pseudo-capsule encasing the PMMA spacer is opened and autogenous bone graft is placed within a well-contained cavity. PMMA: polymethyl methacrylate.

minimal systemic toxicity.<sup>23</sup> The various options include commercially available antibiotic impregnated polymethyl methacrylate (PMMA) beads,<sup>24,25</sup> antibiotic-loaded PMMA bone cement spacers<sup>26,27</sup> and antibiotic-loaded PMMA-coated IM rods.<sup>28</sup> Even local application of vancomycin to the operative site has appeared to reduce infection in high-risk surgeries.<sup>29</sup>

Antibiotic beads are used in contaminated open wounds with smaller sized bone and soft tissue voids.<sup>30</sup> They are commercially prepared and relatively easy to remove. It is indicated when stability of the fracture is maintained and short-term filling is desired.

A two-stage approach with antibiotic-laden spacer and subsequent reconstruction appears to be relatively simple, effective and predictable compared to other elaborate means.<sup>31</sup> Masquelet and Begue<sup>27</sup> described the technique of antibiotic cement spacer-induced membrane and delayed bone grafting. This technique has high success and low complication rates for traumatic and infection-related bone defects.<sup>26,31,32</sup> At debridement, sizable defects are temporarily filled with antibiotic-laden cement which also provides structural support and prevents fibrous ingrowth. Since PMMA curing is exothermic, heat injury and denaturing of impregnated drugs are possible. Heat stable water-soluble drugs such as aminoglycosides, vancomycin and imipenem are preferred. Combining two or more antibiotics in a single spacer is common and shown to be synergistic *in vivo*.<sup>33</sup> The amount of antibiotics used is typically up to 10% by weight for PJI. For example, 0.5–1 g of gentamicin and 2–4 g of vancomycin is mixed with 40 g of PMMA cement in our usual practice. Higher concentrations of antibiotics may be considered, as structural integrity is less relevant to OAI. The mixing of PMMA is performed without vacuum, so that porosities, irregularities and the surface area for drug release are increased.<sup>34</sup>

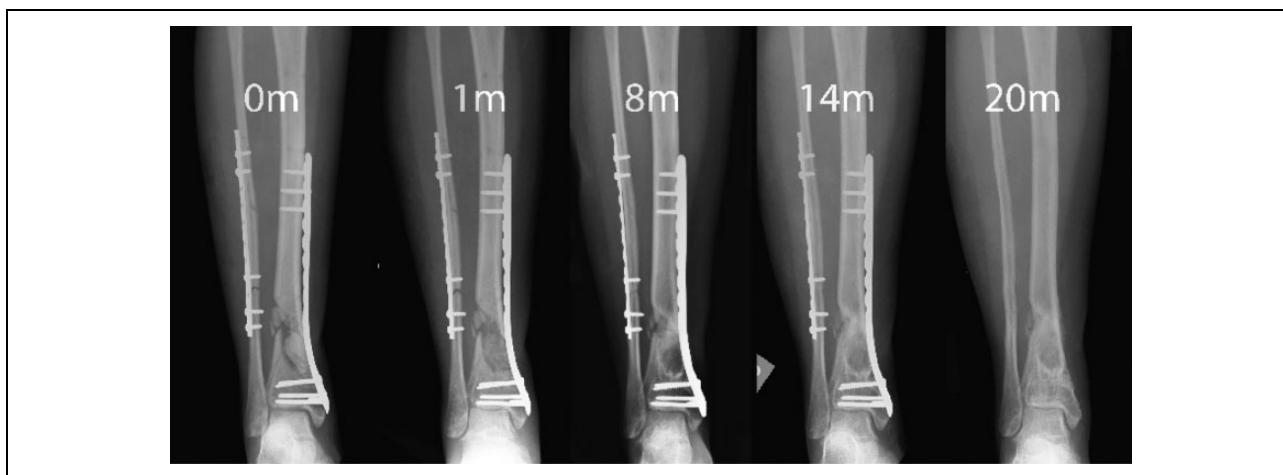
The rate of antibiotic elution varies between drugs and geometries of the spacer.<sup>35</sup> It should be noted that a high concentration is released within a very short period hours after implantation, and the local concentration is exponentially reduced within a few days.<sup>36</sup> Since an inhibitory concentration is not reliably maintained after 2 weeks, it is mandatory to supplement local antibiotics with systemic therapy.<sup>37</sup> Retained PMMA spacers can become a nidus for infection and should therefore be routinely removed.

Second-stage cancellous bone grafting is performed after 6–8 weeks. A pseudo-membrane can usually be found enclosing the PMMA spacer. Although the cellular and molecular mechanism behind this induced membrane is still being studied, it is usually vascular and rich in growth factors.<sup>26</sup> Tissue samples are obtained to document clearance of infection, and graft material is placed within this viable clean cavity.<sup>38,39</sup> Placement of bone graft and bone substitutes in the presence of uncontrolled infection is contraindicated (Figures 2 and 3).

## Specific challenging scenarios

### Massive bone defects

Bone defects are common in OAI, and sometimes a necessary evil resulting from adequate debridement of the sequestrum. When such defects are segmental, fracture healing is compromised. A plethora of techniques exists in the management of bone defects.<sup>40</sup> It is repeatedly mentioned that priority must be given for eradication of infection before tackling of bone defects.<sup>41</sup> The majority of smaller defects of less than 4 cm is usually handled successfully with the two-stage antibiotic PMMA spacer-induced membrane technique mentioned above. A study reported reduced reinfection rates when bone graft is mixed with local antibiotics.<sup>42</sup>



**Figure 3.** Serial radiograph of the same patient from before cement removal and bone grafting (0 m) showing union and remodelling up to 20 months.

A combination of techniques can be used to archive success in massive defects.<sup>43</sup> Distraction osteogenesis with circular fixators is useful for larger segmental defects especially when realignment of deformities is also desired.<sup>44</sup> The risks are refractures, pin tract infections, soft tissue impingement and neurovascular complications.<sup>45</sup> Internal fixation augmentation after docking shortens the time needed for external fixation without considerable risk of reinfection.<sup>46,47</sup> The Papineau technique employs open cancellous bone grafting for problematic osseous defects with overlying soft tissue defect with high rate of reported success<sup>48</sup>; however, the need for repetitive dressing is intensive from the nursing perspective and wound healing by secondary intension and relatively slow.

Tibialization of the fibula or graft-induced tibiofibular synostosis is an option for isolated tibial defects with an intact fibula.<sup>49</sup> Free vascularized bone transfers are technically demanding but useful for massive defects at a slight danger of flap loss, stress fractures and the need for extended periods of protection.

### Soft tissue defects

Routine wound closure and avoidance of exposed bone and hardware are recommended. Suction drainage should be placed into deep cavities and potential dead spaces to prevent retention of haematoma. Locations with thin soft tissue envelope such as the clavicle, patella and distal tibia are especially difficult, and primary closure can be challenging even when the defect is as small as 2 cm.

Flaps are needed for severe soft tissue defects. Free tissue transfer in young patients has high reported success rate even when implants are transiently exposed.<sup>50–52</sup> Risk factors for failure of free tissue transfer are tobacco smoking, renal or liver failure, immune deficiency, chronic hypoxia, malignancy, diabetes, old age, steroid use, alcoholism and substance abuse.<sup>53</sup>

Acute shortening is relatively easy and safe,<sup>54,55</sup> effectively relieving soft tissue tension and reducing dead space. It is particularly useful when there is combined soft tissue and bone defect, optionally followed by distraction osteogenesis.

Negative pressure wound therapy (NPWT) may be used to assist wound coverage accelerate granulation formation and removal of exudate in OAI. It is a useful bridging therapy while waiting for granulation base to develop for skin grafting or to accelerate healing by secondary intension in smaller defects. Importantly, early closure of open fractures by 5–7 days remains the best way to reduce the risk of nosocomial infection, and prolonged NPWT should not be used as a substitute for early wound closure and flap coverage.<sup>56</sup>

### Infection after IM nailing

OAI after IM nailing are uniquely challenging to manage. The IM canal is surgically less accessible, and diagnosis is more likely to be delayed. Treatment is based upon the same principles of stabilization, systemic antibiotics, surgical debridement, soft tissue coverage and staged bone defect management.<sup>57</sup> Makridis et al.<sup>58</sup> devised a surgical management protocol based on three different stages of infection. For early infections, implant retention with or without debridement is sufficient. For delayed infections, debridement, reaming and nail exchange with usual or antibiotic laden implants are suggested. For late infections, debridement, nail exchange or conversion to external fixation is recommended.

Antibiotic cement-coated rods are increasingly being used for IM infections. A number of small series reported success using them as temporary means for fracture stabilization and local bacterial killing,<sup>59–62</sup> followed by refixation with a new IM nail around 2 months later. A large bore chest tube can be used as an economical mould in which

PMMA is injected and cured around a rush pin or an Ender's nail.<sup>63</sup> When axial and rotational stability is required, PMMA-coated small diameter interlocking nails can be used<sup>63</sup> or antibiotic beads can be placed within slotted nails to attain a similar effect.

Reaming effectively removes infected IM debris and bone. The reamer irrigator aspirator (RIA) is a specialized single use reamer which allows simultaneous irrigation and suction within the IM cavity. A number of small studies<sup>64–66</sup> have reported a success rate of 96–100% using RIA and antibiotic cement rods to treat IM osteomyelitis. RIA appears safe, although more studies are needed to confirm its theoretical advantages in infection, prevention of fat embolism and prevention of thermal necrosis.

### Articular involvement

Synovial joints are poorly perfused inherent dead spaces with vulnerable cartilage. Articular involvement is notoriously difficult to manage in OAI. Involvement of the knee and ankle is associated with high-energy tibial plateau and pilon fractures. Shoulder and elbow OAI may lead to very poor results.

Based on experience, we routinely immobilize infected joints after debridement. This is notably dissimilar to PJI where cartilage preservation is irrelevant, and mobilization is usually allowed with articulated antibiotic-loaded spacers. With immobilization, stiffness is common but control of infection is usually more predictable. An uncontrolled infection in a synovial joint is worse than a stiff joint with relatively preserved cartilage. After control of the infection, it is possible to regain significant functional ranges by open or arthroscopic releases in the shoulder, elbow and knee.

Arthrodesis is considered when salvage of a destroyed joint is impossible.<sup>67</sup> Prosthetic replacement should be carried out in two stages with antibiotic-impregnated spacers after complete clearance of infection in order to minimize the risk of contamination.<sup>68</sup> Tumour prosthesis replacement of large defects carries around one-quarter risk of reinfection.<sup>69</sup>

Amputation is indicated when there are significant systemic adverse factors. Those with considerable soft tissue defects are less suitable for joint prosthesis and more suited for amputation or fusion.<sup>70</sup> In special circumstances, amputations may be performed distal to the infection to reduce mechanical and vascular load.<sup>71</sup>

### Systemic treatment

Pharmacological treatment of OAI is mandatory. This can be divided into three stages: empirical treatment, specific targeted treatment and occasional need for long-term suppression. In the selection of antibiotics, bacterial susceptibility, bone penetration and side effects should be considered.

### Empirical antibiotics

Empirical intravenous antibiotics can successfully treat early and superficial infections that do not have well-established biofilms. Antibiotics do not penetrate into haematoma, seroma, abscess or devitalized bone and necrotic soft tissue. High-dose intravenous administration can best ensure bactericidal concentrations in poorly perfused bone and peri-implant areas.

*Staphylococcus aureus*, in particular, methicillin-sensitive *S. aureus*, remains a common cause of OAI in the community; anti-staphylococcal antibiotics such as penicillinase-resistant penicillin (e.g. cloxacillin) or first-generation cephalosporin (e.g. cefazolin) are first-line drugs for empirical coverage. In patients with previous history of methicillin-resistant *S. aureus* infections, and those with prolonged hospitalization or institutional care, glycopeptide such as vancomycin or teicoplanin should be used for empirical treatment. Third-generation cephalosporin such as cefotaxime or ceftriaxone should be considered for OAI around the perineum,<sup>2</sup> elderly, diabetics or immunocompromised patients because they are at higher risk of gram-negative infections.

In delayed and late infections occurring more than 3 weeks after osteosynthesis, less virulent organisms such as coagulase negative staphylococci (CNS) or unusual organisms are common. Empirical treatment must not interfere with a rapid microbiological diagnosis. Unless in severe sepsis, empirical therapy is withheld until deep tissue and fluid samples are obtained. It is important to note that 80–90% of CNS are resistant to methicillin. Prolonged treatment with a targeted drug is needed in delayed cases because bone and implant involvement is usually established. Misidentification of delayed or late OAIs and inadequacy in antibiotic treatment commonly leads to persistent bacterial residence and development of resistance.

### Targeted antibiotics

Resistant strains can account for more than 50% of *S. aureus* and 32% of all organisms that cause OAI.<sup>2</sup> Target-specific therapy should begin as soon as culture isolates and antibiotic susceptibility patterns become available. When a specific microorganism is identified, the broad-spectrum empirical drug is changed to a narrow-spectrum target-specific antibiotic to minimize host flora suppression and emergence of resistance. Polymicrobial growth is associated with contaminated open fractures and poor host immunity. A combination of drugs is usually necessary.

For staphylococci infections, combined therapies with rifampicin have shown increased in vitro and in vivo eradication compared to monotherapy with quinolone or  $\beta$ -lactams and superior biofilm penetration. A few prospective studies demonstrated the cure rates of 69–100% using a 6-month rifampicin–quinolone combination regimen, especially in earlier infections.<sup>72,73</sup>

**Table 1.** Recommended antibiotics (choice of antibiotics should be guided by antibiotic susceptibility testing results)<sup>a</sup>.

	Initial treatment	Oral maintenance
Methicillin-susceptible <i>Staphylococcus</i> species	Cloxacillin or flucloxacillin + rifampicin or Cephazolin + rifampicin	Quinolone + rifampicin or Co-trimoxazole <sup>b</sup> or Fusidic acid <sup>b</sup> or Minocycline or Clindamycin or Linezolid
Methicillin-resistant <i>Staphylococcus</i> species	Vancomycin or Daptomycin	Quinolone + rifampicin or Co-trimoxazole <sup>b</sup> or Fusidic acid <sup>b</sup> or Minocycline or Clindamycin or Linezolid
<i>Streptococcus</i>	Penicillin G or Ceftriaxone Vancomycin	Amoxicillin or Clindamycin or Linezolid
<i>Enterococcus</i> – penicillin susceptible	Ampicillin	
<i>Enterococcus</i> – penicillin resistant	Vancomycin or Daptomycin or Linezolid	
Enterobacteriaceae	β-Lactam	Ciprofloxacin
<i>Pseudomonas aeruginosa</i>	Ceftazidime or Meropenem	Ciprofloxacin
<i>Propionibacterium</i>	Penicillin G or Clindamycin	Amoxicillin or Clindamycin

<sup>a</sup>Modified from Mandell, Douglas, and Bennett's principles and practices of infectious diseases (Eighth edition). Gerald L. Mandell, John E. Bennett, Raphael Dolin. Chapter 107. Authors: Werner Zimmerli, Parham Sendi.

<sup>b</sup>Should be used in combination with other oral antibiotics, except rifampicin.

### Duration of antibiotics

In all situations, we recommend initial high-dose intravenous treatment for 3 weeks. Prolonged therapy is always necessary in delayed or late infections with implants. In patients showing rapid response, this may be changed to oral drugs with high bioavailability in bone.<sup>74</sup> A peripherally inserted central catheter simplifies long-term venous access with minimal risks. It is necessary to regularly monitor inflammatory parameters, local conditions and radiological evidence of fracture healing and implant loosening. Antibiotics are stopped only when there is clinical resolution of infection, normalization of biochemical markers and radiological signs of good fracture stability, no implant loosening and progressive healing. When in doubt, positron emission tomography – computed tomography (PET-CT) scans are useful in monitoring both the status of infection and fracture healing.

The minimal duration of antimicrobial therapy for delayed OAI is 6 weeks with retained implants when patients have optimal response both clinically and biochemically. This is increased to 3 months or more if initial control is not rapid and adverse factors local or systemic are present. The duration can be reduced to 3 weeks if all implants are removed with good local control and fracture healing (Table 1).

### Failed eradication and long-term suppression

Failure of control and re-emergence of infection usually happens within 3 months after stopping antibiotics.<sup>75</sup> Long-term suppression therapy is indicated when fracture healing is incomplete or when surgical treatment is impossible. Suppression should not be a routine alternative to surgery because of increased risk of adverse drug reactions and bacterial resistance. Fracture healing can occur during drug suppression, and implant removal is still strongly advised afterwards.

### Adverse effects

Adverse drug reactions often occur when antibiotic treatment is prolonged. These include allergy, drug rash, antibiotic-associated colitis, bone marrow suppression, leukopenia, thrombocytopenia and drug fever. Specific side effects for rifampicin include liver impairment and thrombocytopenia. For vancomycin, patients may develop renal impairment. Patients on daptomycin can develop myositis with need to monitor creatine kinase.<sup>76</sup> Monitory measures for side effects are necessary at constant time intervals. Patients suspected to be suffering from adverse reactions should receive advice from infectious disease specialists.



Drug fever presents a specific diagnostic dilemma. Unlike uncontrolled infection, there is improved local symptoms and signs, improving erythrocyte sedimentation rate (ESR), C-Reactive Protein (CRP) and low leukocyte counts. Antibiotics are stopped or switched to a different class and patients are observed closely without additional surgery. Alternatively, if local and systemic features remain doubtful, strong consideration is given to perform additional debridement together with modification of antibiotics.

### Ongoing developments

Dipstick leukocyte esterase colorimetric measurement is recently being evaluated as a cost-effective and rapid test using synovial aspirates in PJI with high sensitivity and specificity.<sup>77</sup> The role of this test has not yet been investigated in OAI. Novel molecular markers based on immunoglobulin G (IgG) antibodies are being studied as an alternative technique for pathogen identification.<sup>78</sup> In addition to sonification, electrical stimulation and laser-generated shockwaves may enhance detachment of biofilms organisms from implants for diagnosis.<sup>79,80</sup>

Implant designs are being altered for the prevention and control of OAI in a number of ways.<sup>81</sup> Specialized coating materials<sup>82</sup> and drug eluting implants are currently being developed.<sup>83,84</sup> Nanostructured surface finishing<sup>85</sup> and hydrophilic surface materials such as polyethylene oxide,<sup>86</sup> bioactive copper and silver may inhibit bacterial adhesion and biofilm formation. Prophylactic use of antibiotic-coated nails is being investigated for open fractures.<sup>87</sup>

A pilot study showed that local application of bismuth thiols may be effective in preventing infections in open fractures.<sup>88</sup> Local antibiotic delivery and dead space control maybe enhanced using specialized water-soluble gels or polymers other than PMMA which are also less exothermic.<sup>89,90</sup> The role of biological agents such as bone morphological proteins that speed up bone healing is being investigated in OAI.<sup>91,92</sup> The cationic steroid antibiotic CSA-90 is a novel drug being investigated for both bone stimulation and bactericidal properties.<sup>93</sup>

### Summary

Overall, the subject of OAI remains to be challenging and is predominantly an experience-based practice. Once more, we emphasize the importance of maintaining mechanical stability in any treatment strategy. Two-stage use of antibiotic-loaded PMMA spacers appears to result in more predictable success than single-stage strategies. Much knowledge gaps remain to be filled by properly conducted clinical research. Investigations in novel techniques and robust comparative studies are particularly needed. While randomized studies are hard to conduct in this heterogeneous group of patients, establishment of large

international multicentre bone infection registries may provide useful insights.

### Authors' contribution

This work has not been published and is not being considered for publication elsewhere. All co-authors have made significant contributions to the work and have read and approved the submission of manuscript.

### Declaration of conflicting interests

The author(s) declared no potential conflicts of interest with respect to the research, authorship, and/or publication of this article.

### Funding

The author(s) received no financial support for the research, authorship, and/or publication of this article.

### References

1. Has B, Nagy A, Pavic R, et al. External fixation and infection of soft tissues close to fracture localization. *Mil Med* 2006; 171(1): 88–91.
2. Torbert JT, Joshi M, Moraff A, et al. Current bacterial speciation and antibiotic resistance in deep infections after operative fixation of fractures. *J Orthop Trauma* 2015; 29(1): 7–17.
3. Berkes M, Obrebsky WT, Scannell B, et al. Maintenance of hardware after early postoperative infection following fracture internal fixation. *J Bone Joint Surg Am* 2010; 92(4): 823–828.
4. Rightmire E, Zurakowski D and Vrahas M. Acute infections after fracture repair: management with hardware in place. *Clin Orthop Relat Res* 2008; 466(2): 466–472.
5. Naique SB, Pearse M and Nanchahal J. Management of severe open tibial fractures: the need for combined orthopaedic and plastic surgical treatment in specialist centres. *J Bone Joint Surg Br* 2006; 88(3): 351–357.
6. Nasell H, Adami J, Samnegard E, et al. Effect of smoking cessation intervention on results of acute fracture surgery: a randomized controlled trial. *J Bone Joint Surg Am* 2010; 92(6): 1335–1342.
7. Romano CL, Manzi G, Logoluso N, et al. Value of debridement and irrigation for the treatment of peri-prosthetic infections. A systematic review. *Hip Int* 2012; 22 (Suppl 8): S19–S24.
8. Hofmann GO, Bar T and Bühren V. The osteosynthesis implant and early postoperative infection: healing with or without removal of the material? *Chirurg* 1997; 68(11): 1175–1180.
9. Schmidt AH and Swiontkowski MF. Pathophysiology of infections after internal fixation of fractures. *J Am Acad Orthop Surg* 2000; 8(5): 285–291.
10. McNeur JC. The management of open skeletal trauma with particular reference to internal fixation. *J Bone Joint Surg Br* 1970; 52(1): 54–60.
11. Osmon DR, Berbari EF, Berendt AR, et al. Executive summary: diagnosis and management of prosthetic joint



- infection: clinical practice guidelines by the infectious diseases society of America. *Clin Infect Dis* 2013; 56(1): 1–10.
12. Chen CE, Ko JY, Wang JW, et al. Infection after intramedullary nailing of the femur. *J Trauma* 2003; 55(2): 338–344.
  13. Court-Brown CM, Keating JF and McQueen MM. Infection after intramedullary nailing of the tibia. Incidence and protocol for management. *J Bone Joint Surg Br* 1992; 74(5): 770–774.
  14. Struijs PA, Poolman RW and Bhandari M. Infected nonunion of the long bones. *J Orthop Trauma* 2007; 21(7): 507–511.
  15. Olszewski D, Streubel PN, Stucken C, et al. 3rd. The fate of patients with a “surprise” positive culture after nonunion surgery. *J Orthop Trauma* 2016 Jan; 30(1): e19–23.
  16. Al-Mayahi M, Betz M, Muller DA, et al. Remission rate of implant-related infections following revision surgery after fractures. *Int Orthop* 2013; 37(11): 2253–2258.
  17. Hughes MS, Moghadamian ES, Yin LY, et al. Comparison of bulb syringe, pressurized pulsatile, and hydrosurgery debridement methods for removing bacteria from fracture implants. *Orthopedics* 2012; 35(7): e1046–e1050.
  18. Saridis A, Panagiotopoulos E, Tyllianakis M, et al. The use of the Ilizarov method as a salvage procedure in infected nonunion of the distal femur with bone loss. *J Bone Joint Surg Br* 2006; 88(2): 232–237.
  19. Paley D, Lamm BM, Katsenis D, et al. Treatment of malunion and nonunion at the site of an ankle fusion with the Ilizarov apparatus. Surgical technique. *J Bone Joint Surg Am* 2006; 88(Suppl 1 Pt 1): 119–134.
  20. Katsenis D, Bhav A, Paley D, et al. Treatment of malunion and nonunion at the site of an ankle fusion with the Ilizarov apparatus. *J Bone Joint Surg Am* 2005; 87(2): 302–309.
  21. Emara KM and Allam MF. Ilizarov external fixation and then nailing in management of infected nonunions of the tibial shaft. *J Trauma* 2008; 65(3): 685–691.
  22. Obrebsky WT, Molina CS, Collinge C, et al. Current practice in the initial management of open fractures among orthopaedic trauma surgeons. *J Orthop Trauma*. 2014 Aug; 28(8): e198–202.
  23. Springer BD, Lee G-C, Osmon D, et al. Systemic safety of high-dose antibiotic-loaded cement spacers after resection of an infected total knee arthroplasty. *Clin Orthop Relat Res* 2004; 427: 47–51.
  24. Ostermann PA, Seligson D and Henry SL. Local antibiotic therapy for severe open fractures. A review of 1085 consecutive cases. *J Bone Joint Surg Br* 1995; 77(1): 93–97.
  25. Keating JF, Blachut PA, O’Brien PJ, et al. Reamed nailing of open tibial fractures: does the antibiotic bead pouch reduce the deep infection rate? *J Orthop Trauma* 1996; 10(5): 298–303.
  26. Wong TM, Lau TW, Li X, et al. Masquelet technique for treatment of posttraumatic bone defects. *Scientific World J* 2014; (2014): 710302.
  27. Masquelet AC and Begue T. The concept of induced membrane for reconstruction of long bone defects. *Orthop Clin North Am* 2010; 41(1): 27–37.
  28. Lehner B, Fleischmann W, Becker R, et al. First experiences with negative pressure wound therapy and instillation in the treatment of infected orthopaedic implants: a clinical observational study. *Int Orthop* 2011; 35(9): 1415–1420.
  29. Yan H, He J, Chen S, et al. Intrawound application of vancomycin reduces wound infection after open release of post-traumatic stiff elbows: a retrospective comparative study. *J Shoulder Elbow Surg* 2014; 23(5): 686–692.
  30. Ueng SW, Wei FC and Shih CH. Management of femoral diaphyseal infected nonunion with antibiotic beads local therapy, external skeletal fixation, and staged bone grafting. *J Trauma* 1999; 46(1): 97–103.
  31. Giannoudis PV, Faour O, Goff T, et al. Masquelet technique for the treatment of bone defects: tips-tricks and future directions. *Injury* 2011; 42(6): 591–598.
  32. McKee MD, Li-Bland EA, Wild LM, et al. A prospective, randomized clinical trial comparing an antibiotic-impregnated bioabsorbable bone substitute with standard antibiotic-impregnated cement beads in the treatment of chronic osteomyelitis and infected nonunion. *J Orthop Trauma* 2010; 24(8): 483–490.
  33. Neut D, de Groot EP, Kowalski RSZ, et al. Gentamicin-loaded bone cement with clindamycin or fusidic acid added: biofilm formation and antibiotic release. *J Biomed Mater Res Part A* 2005; 73(2): 165–170.
  34. van de Belt H, Neut D, Uges DRA, et al. Surface roughness, porosity and wettability of gentamicin-loaded bone cements and their antibiotic release. *Biomaterials* 2000; 21(19): 1981–1987.
  35. Anagnostakos K and Kelm J. Enhancement of antibiotic elution from acrylic bone cement. *J Biomed Mater Res B Appl Biomater* 2009; 90(1): 467–475.
  36. Penner MJ, Duncan CP and Masri BA. The in vitro elution characteristics of antibiotic-loaded CMW and Palacos-R bone cements. *J Arthroplasty* 1999; 14(2): 209–214.
  37. Inzana JA, Schwarz EM, Kates SL, et al. A novel murine model of established Staphylococcal bone infection in the presence of a fracture fixation plate to study therapies utilizing antibiotic-laden spacers after revision surgery. *Bone* 2015; 72: 128–36.
  38. Stafford PR and Norris BL. Reamer-irrigator-aspirator bone graft and bi Masquelet technique for segmental bone defect nonunions: a review of 25 cases. *Injury* 2010; 41(Suppl 2): S72–77.
  39. Donegan DJ, Scolaro J, Matuszewski PE, et al. Staged bone grafting following placement of an antibiotic spacer block for the management of segmental long bone defects. *Orthopedics* 2011; 34(11): e730–e735.
  40. Wiese A and Pape HC. Bone defects caused by high-energy injuries, bone loss, infected nonunions, and nonunions. *Orthop Clin North Am* 2010; 41(1): 1–4.
  41. Rodriguez-Merchan EC and Forriol F. Nonunion: general principles and experimental data. *Clin Orthop Relat Res* 2004; 419: 4–12.
  42. Chan YS, Ueng SW, Wang CJ, et al. Antibiotic-impregnated autogenic cancellous bone grafting is an effective and safe

- method for the management of small infected tibial defects: a comparison study. *J Trauma* 2000; 48(2): 246–255.
43. Lai D, Chen CM, Chiu FY, et al. Reconstruction of juxta-articular huge defects of distal femur with vascularized fibular bone graft and Ilizarov's distraction osteogenesis. *J Trauma* 2007; 62(1): 166–173.
  44. Ali F and Saleh M. Treatment of distal femoral nonunions by external fixation with simultaneous length and alignment correction. *Injury* 2002; 33(2): 127–34.
  45. Papakostidis C, Bhandari M and Giannoudis PV. Distraction osteogenesis in the treatment of long bone defects of the lower limbs: effectiveness, complications and clinical results; a systematic review and meta-analysis. *Bone Joint J* 2013; 95(12): 1673–1680.
  46. Oh CW, Apivatthakakul T, Oh JK, et al. Bone transport with an external fixator and a locking plate for segmental tibial defects. *Bone Joint J* 2013; 95(12): 1667–1672.
  47. Sewell MD, Spiegelberg BG, Hanna SA, et al. Non-invasive extendible endoprostheses for limb reconstruction in skeletally-mature patients. *J Bone Joint Surg Br* 2009; 91(10): 1360–1365.
  48. Tulner SAF, Schaap GR, Strackee SD, et al. Long-term results of multiple-stage treatment for posttraumatic osteomyelitis of the tibia. *J Trauma Acute Car Surg* 2004; 56(3): 633–642.
  49. Tuli SM. Tibialization of the fibula: a viable option to salvage limbs with extensive scarring and gap nonunions of the tibia. *Clin Orthop Relat Res* 2005; 431: 80–84.
  50. Chim H, Sontich JK and Kaufman BR. Free tissue transfer with distraction osteogenesis is effective for limb salvage of the infected traumatized lower extremity. *Plast Reconstr Surg* 2011; 127(6): 2364–2372.
  51. Tan KJ, Lim CT and Lim AY. The use of muscle flaps in the salvage of infected exposed implants for internal fixation. *J Bone Joint Surg Br* 2010; 92(3): 401–405.
  52. Ovaska MT, Madanat R, Tukiainen E, et al. Flap reconstruction for soft-tissue defects with exposed hardware following deep infection after internal fixation of ankle fractures. *Injury* 2014; 45(12): 2029–2034.
  53. Gonzalez MH and Weinzeig N. Muscle flaps in the treatment of osteomyelitis of the lower extremity. *J Trauma* 2005; 58(5): 1019–1023.
  54. El-Rosasy MA. Acute shortening and re-lengthening in the management of bone and soft-tissue loss in complicated fractures of the tibia. *J Bone Joint Surg Br* 2007; 89(1): 80–88.
  55. Sen C, Eralp L, Gunes T, et al. An alternative method for the treatment of nonunion of the tibia with bone loss. *J Bone Joint Surg Br* 2006; 88(6): 783–789.
  56. Bhattacharyya T, Mehta P, Smith M, et al. Routine use of wound vacuum-assisted closure does not allow coverage delay for open tibia fractures. *Plast Reconstr Surg* 2008; 121(4): 1263–1266.
  57. Mouzopoulos G, Kanakaris NK, Kontakis G, et al. Management of bone infections in adults: the surgeon's and microbiologist's perspectives. *Injury* 2011; 42(Suppl 5): S18–23.
  58. Makridis KG, Tosounidis T and Giannoudis PV. Management of infection after intramedullary nailing of long bone fractures: treatment protocols and outcomes. *Open Orthop J* 2013; 7: 219–226.
  59. Conway J, Mansour J, Kotze K, et al. Antibiotic cement-coated rods: an effective treatment for infected long bones and prosthetic joint nonunions. *Bone Joint J* 2014; 96(10): 1349–1354.
  60. Rodriguez H and Ziran BH. Temporary antibiotic cement-covered gamma nail spacer for an infected nonunion of the proximal femur. *Clin Orthop Relat Res* 2007; 454: 270–274.
  61. Qiang Z, Jun PZ, Jie XJ, et al. Use of antibiotic cement rod to treat intramedullary infection after nailing: preliminary study in 19 patients. *Arch Orthop Trauma Surg* 2007; 127(10): 945–951.
  62. Wasko MK and Borens O. Antibiotic cement nail for the treatment of posttraumatic intramedullary infections of the tibia: midterm results in 10 cases. *Injury* 2013; 44(8): 1057–1060.
  63. Paley D and Herzenberg JE. Intramedullary infections treated with antibiotic cement rods: preliminary results in nine cases. *J Orthop Trauma* 2002; 16(10): 723–729.
  64. Kanakaris N, Gudipati S, Tosounidis T, et al. The treatment of intramedullary osteomyelitis of the femur and tibia using the reamer-irrigator-aspirator system and antibiotic cement rods. *Bone Joint J* 2014; 96(6): 783–188.
  65. Zalavras CG and Sirkin M. Treatment of long bone intramedullary infection using the RIA for removal of infected tissue: indications, method and clinical results. *Injury* 2010; 41(Suppl 2): S43–S47.
  66. Cox G, Jones E, McGonagle D, et al. Reamer-irrigator-aspirator indications and clinical results: a systematic review. *Int Orthop* 2011; 35(7): 951–956.
  67. Hulscher JB, Te Velde EA, Schuurman AH, et al. Arthrodesis after osteosynthesis and infection of the ankle joint. *Injury* 2001; 32(2): 145–152.
  68. Hsieh PH, Chang YH, Chen SH, et al. Staged arthroplasty as salvage procedure for deep hip infection following intertrochanteric fracture. *Int Orthop* 2006; 30(4): 228–232.
  69. Larson AN, Hanssen AD and Cass JR. Does prior infection alter the outcome of TKA after tibial plateau fracture? *Clin Orthop Relat Res* 2009; 467(7): 1793–1799.
  70. Angelini A, Henderson E, Trovarelli G, et al. Is there a role for knee arthrodesis with modular endoprostheses for tumor and revision of failed endoprostheses? *Clin Orthop Relat Res* 2013; 471(10): 3326–3335.
  71. Berlemont M and Decoulx J. Amputation below the fracture site in pseudarthrosis complicated by infection or vascular lesion. *Rev Chir Orthop Reparatrice Appar Mot* 1985; 71(8): 527–536.
  72. Zimmerli W, Widmer AF, Blatter M, et al. Role of rifampin for treatment of orthopedic implant-related staphylococcal infections: a randomized controlled trial. *JAMA* 1998; 279(19): 1537–1541.
  73. Drancourt M, Stein A, Argenson JN, et al. Oral rifampin plus ofloxacin for treatment of Staphylococcus-infected

- orthopedic implants. *Antimicrob Agents Chemother* 1993; 37(6): 1214–1218.
74. Swiontkowski MF, Hanel DP, Vedder NB, et al. A comparison of short- and long-term intravenous antibiotic therapy in the postoperative management of adult osteomyelitis. *J Bone Joint Surg Br* 1999; 81(6): 1046–1050.
  75. Byren I, Bejon P, Atkins BL, et al. One hundred and twelve infected arthroplasties treated with ‘DAIR’ (debridement, antibiotics and implant retention): antibiotic duration and outcome. *J Antimicrob Chemother* 2009; 63(6): 1264–1271.
  76. Beiras-Fernandez A, Vogt F, Sodian R, et al. Daptomycin: a novel lipopeptide antibiotic against Gram-positive pathogens. *Infect Drug Resist* 2010; 3: 95–101.
  77. Tischler EH, Cavanaugh PK and Parvizi J. Leukocyte esterase strip test: matched for musculoskeletal infection society criteria. *J Bone Joint Surg Am* 2014; 96(22): 1917–1920.
  78. Gedbjerg N, LaRosa R, Hunter JG, et al. Anti-glucosaminidase IgG in sera as a biomarker of host immunity against *Staphylococcus aureus* in orthopaedic surgery patients. *J Bone Joint Surg Am* 2013; 95(22): e171.
  79. Del Pozo JL, Rouse MS, Euba G, et al. The electricidal effect is active in an experimental model of staphylococcus epidermidis chronic foreign body osteomyelitis. *Antimicrob Agents Chemother* 2009; 53(10): 4064–4068.
  80. Kizhner V, Krespi YP, Hall-Stoodley L, et al. Laser-generated shockwave for clearing medical device biofilms. *Photomed Laser Surg* 2011; 29(4): 277–282.
  81. Schlegel U and Perren SM. Surgical aspects of infection involving osteosynthesis implants: implant design and resistance to local infection. *Injury* 2006; 37(Suppl 2): S67–S73.
  82. Moriarty TF, Schlegel U, Perren S, et al. Infection in fracture fixation: can we influence infection rates through implant design? *J Mater Sci Mater Med* 2010; 21(3): 1031–1035.
  83. Fei J, Yu HJ, Pan CJ, et al. Efficacy of a norvancomycin-loaded, PDLLA-coated plate in preventing early infection of rabbit tibia fracture. *Orthopedics* 2010; 33(5): 310.
  84. Stewart S, Barr S, Engiles J, et al. Vancomycin-modified implant surface inhibits biofilm formation and supports bone-healing in an infected osteotomy model in sheep: a proof-of-concept study. *J Bone Joint Surg Am* 2012; 94(15): 1406–1415.
  85. Campoccia D, Montanaro L and Arciola CR. A review of the biomaterials technologies for infection-resistant surfaces. *Biomaterials* 2013; 34(34): 8533–8554.
  86. Roosjen A, Kaper HJ, van der Mei HC, et al. Inhibition of adhesion of yeasts and bacteria by poly(ethylene oxide)-brushes on glass in a parallel plate flow chamber. *Microbiology* 2003; 149(Pt 11): 3239–3246.
  87. Fuchs T, Stange R, Schmidmaier G, et al. The use of gentamicin-coated nails in the tibia: preliminary results of a prospective study. *Arch Orthop Trauma Surg* 2011; 131(10): 1419–1425.
  88. Penn-Barwell JG, Baker B and Wenke JC. Local bismuth thiols potentiate antibiotics and reduce infection in a contaminated open fracture model. *J Orthop Trauma* 2015; 29(2): e73–e78.
  89. Wellisz T, An YH, Wen X, et al. Infection rates and healing using bone wax and a soluble polymer material. *Clin Orthop Relat Res* 2008; 466(2): 481–486.
  90. Penn-Barwell JG, Murray CK and Wenke JC. Local antibiotic delivery by a bioabsorbable gel is superior to PMMA bead depot in reducing infection in an open fracture model. *J Orthop Trauma* 2014; 28(6): 370–375.
  91. Chen X, Schmidt AH, Tsukayama DT, et al. Recombinant human osteogenic protein-1 induces bone formation in a chronically infected, internally stabilized segmental defect in the rat femur. *J Bone Joint Surg Am* 2006; 88(7): 1510–1523.
  92. Brick KE, Chen X, Lohr J, et al. rhBMP-2 modulation of gene expression in infected segmental bone defects. *Clin Orthop Relat Res* 2009; 467(12): 3096–3103.
  93. Schindeler A, Yu NY, Cheng TL, et al. Local delivery of the cationic steroid antibiotic CSA-90 enables osseous union in a rat open fracture model of *Staphylococcus aureus* infection. *J Bone Joint Surg Am* 2015; 97(4): 302–309.